

Article Info

Received: 11 Sept 2022 | Revised Submission: 17 Nov 2022 | Accepted: 05 Dec 2022 | Available Online: 15 Dec 2022

**Technique to Enhance Aesthetics of Patient using Detachable Hollow Cheek
Plumper: A Case Report**

Sanjivani Mamilwad, K. M. Mahale**, Smita Khalikar*** and S. P. Dange*****

ABSTRACT

Increasing age and long standing edentulism leads to the resorption of the maxillary ridge that leads to constriction of arches because of this it causes loss of support from facial musculature and hollow appearance of cheek. Cheek are important in determining the esthetics of face.

Keywords: Cheek plumper; Hollow; Shrunken cheeks; Ridge resorption.

1.0 Introduction

As age increases in edentulous patients the bony mid-face dramatically collapses. The face is a mirror of human body and now a days aesthetics play an important role in terms of social and personal life. Cheeks due to their extreme visibility are an important factor in determining facial aesthetics. The form of cheeks is usually determined by the support provided by the structures like teeth, ridges or dentures. Cheek loss their fullness with extraction of teeth so there is hollow and shrunken appearance of cheeks. Shrunken or hollow cheeks gives person senile appearance and hence have a detrimental psychological effect on the patient.

While replacing missing teeth, it is important that the prosthesis not only replace the missing teeth but also restore the facial form and contours. However in some cases like patients with hollow cheeks, extra support has to be provided. This can be done using cheek plumper or cheek lifting appliances. Cheek plumper or cheek lifting appliances have been used previously for the purpose of improving aesthetics and psychological profile in patients and Use of plumper prosthesis in maxillofacial prosthodontics is also well documented [1,2,3]. Though, there are many techniques like reconstructive plastic surgery with facial implants, or malar augmentation with injectable materials. But,

prosthetic rehabilitation is a preferred treatment option, when due to medical or other reasons a surgical approach is contraindicated [4,5].

There are different types of cheek plumper detachable and nondetachable. Nondetachable cheek plumper has some disadvantages like increased weight, difficulty in insertion, muscle fatigue; interference with masseter and buccinator muscle function and coronoid process of the mandible [6]. It can also not be used in patients with limited mouth opening.

Some authors have used magnets [7,8] and push button detachable cheek plumper [9] as attachments to overcome the demerits of non-detachable cheek plumper. But these magnets and push buttons as attachments also have some disadvantages. Hence, this clinical report focuses on how to enhance facial esthetics of completely edentulous patients with sunken cheeks with the help of a detachable cheek plumper. To avoid heaviness of cheek plumper in this case report it is hollowed using thermacol balls.

2.0 Case Report

A 74-year old patient was reported to department of prosthodontics, as the patient had difficulty in eating and talking and was unhappy with his previous denture as it was loose and his facial appearance was not good with the same denture.

*Corresponding author: Govt. Dental College and Hospital, Aurangabad, India (E-mail: sanjivanism21@gmail.com)

**Govt. Dental College and Hospital, Aurangabad, India

***Govt. Dental College and Hospital, Aurangabad, India

****Govt. Dental College and Hospital, Aurangabad, India

Clinical examination revealed completely edentulous upper and lower ridges, sunken cheek on the both the side. Patient was edentulous for more than 1 year. On extraoral examination it found that shrunk. Patient was conscious of them and desired a prosthesis which would make his face look fuller and healthier and improves his look.

By keeping in mind about patient demand, It was decided to give patient upper and lower complete dentures with detachable cheek plumper for the maxillary denture and patient was apprehensive about heaviness of cheek plumper to it was planned to make hollow cheek plumper.

3.0 Steps in Fabrication of Hollow Cheek Plumper

1. Maxillary and mandibular preliminary impression made in impression compound.
2. Custom tray made and border moulding and final impression made in conventional manner.
3. Jaw relations were recorded. While recording jaw relation insufficient cheek support were noticed and wax was added until required fullness is achieved.
4. Try in was done.
5. Once the try in was done wax plumper were attached to the maxillary denture base on both the side in molar region and were evaluated to give patient a more fuller appearance.
6. The waxed plumper was separated from the waxed denture base.
7. Separated cheek plumper made hollow by removing wax
8. The hollow plumper and complete denture was invested and acrylisation was carried out in conventional manner.
9. Hollowed cheek plumper filled with thermacol ball and thin layer of cold cure acrylic applied over that. After complete polymerization of cold cure button were attached by making hole on plumper.
10. After that in Upper denture one hole was made on the buccal surface of denture to attach the button attachments.
11. The acrylised plumpers were tried in the mouth and button portion placed on denture were placed in the plumper part which corresponded to the attachments in the denture to get snap fit.
12. It was delivered to patient.

Figure 1: Wax Cheek Plumpers



Figure 2: Try in Pt. Mouth

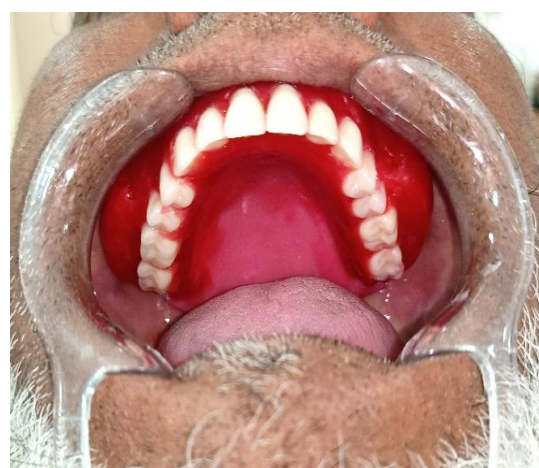


Figure 3: Hollowed Plumper



Figure 4: Investing of Hollowed Plumper



Figure 5: Floating Plumpers

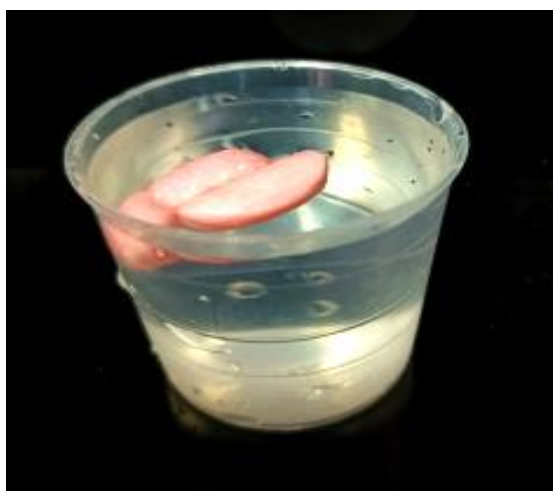

Figure 6: Denture Insertion After Cheek Plumper Attached

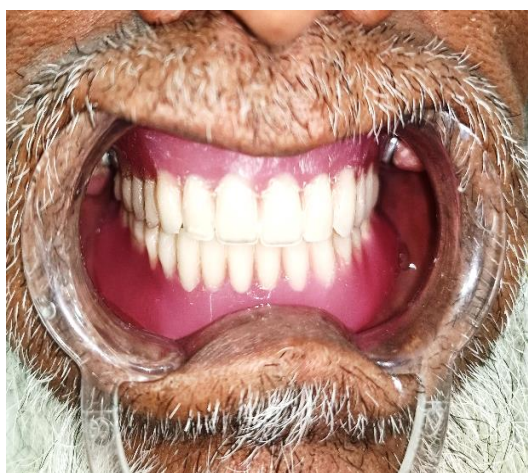

Figure 7: Preoperative




Figure 8: Postoperative



4.0 Discussion

Aging and a long period of edentulousness causes resorption of the maxillary residual ridge resulting in narrowing of the arch and loss of facial muscle support that leads to the sunken appearance of cheeks.[10] Besides age-related factor, loss of subcutaneous fat and elasticity of connective tissue causes the collapsed cheek appearance[10]. Correction of sunken cheeks to enhance the aesthetics of an individual is one of the major challenge for a clinician. There are Multiple options are available for modification of the dentures that provide support to enhance appearance of patient.

Modification of drooped cheek appearance can be done either by invasive or noninvasive approach. The invasive approach includes different strategies such as reconstructive plastic surgical procedures and infusing the botulinum (BOTOX) in the facial muscles.[11] Whereas, the non-invasive management of sunken cheek can be done using prosthetic method. The plastic surgical procedure is a hideous method that may result in a postoperative scar and at times contraindicated in old patients experiencing various medical ailments.

Use of hollow plumper not only support to the sunken cheeks but also enhance the aesthetics and is considered as one of the better treatment options. Preprosthetic correction is also one of the treatment modality available but it might leads a post surgical scar unnecessarily. In a cheek plumper denture stability and retention would be a major problem due to increased medio lateral width and also weight of the denture and may lead to muscle fatigue due to constant strain acting on the muscles but hollowing of plumper reduces that weight[12]. In most of the cases, the fabrication of cheek plumper prosthesis, the procedure described here is a definitive alternative with assured advantages.

5.0 Conclusion

Prosthodontics treatment not only limited to replace the missing teeth but also at same time to enhance the appearance of patient. Article describe simple, inexpensive and non-invasive method to improve facial appearance in patients with hollow faces.

References

- [1] Lazzari JB (1955) Intraoral splint for support of lips in Bells palsy. J Prosthet Dent 5(4): 579–581.
- [2] Larzen SJ, Cartern JF, Abrahamian HA (1976) Prosthetic support for unilateral facial paralysis. J Prosthet Dent 35(2):192–201.
- [3] Hitoshi M, Chiaki K, Takashi O, Hisashi T (2004) Lip plumper prosthesis for a patient with a marginal mandibulectomy: a clinical report. J Prosthet Dent 92(1):23–26.
- [4] Taheri A, Mansoori P. Midfaicial analysis and planning for midface aug- mentation with injectable filling materials : an anatomical approach. JEADV 2012; 26 :714-19.
- [5] Funt DK. Avoiding Malar edema during midface/ cheek augmentation with dermal fillers. J clin aesthet dermatol 2011; 4(12): 32-36.
- [6] Keni NN, Aras M, Chitre V: Customised attachments retained cheek plumper prosthesis: a case report. J Indian Prosthodont Soc. 2012, 12:198-200.
- [7] Deogade SC: Magnet retained cheek plumper in complete denture esthetics: a case report. J Dent (Tehran). 2014, 11:100-105.
- [8] Kamakshi V, Anehosur GV, Nadiger RK: Magnet retained cheek plumper to enhance denture esthetics: case reports. J Indian Prosthodont Soc. 2013, 13:378-381.
- [9] Aggarwal P, Gupta MR, Pawah S, Singh A: An innovative technique to improve complete denture aesthetics using cheek plumper appliance: a case report. Int J Oral Health Med Res. 2016, 3:51-54.
- [10] Petrokovski J, Starinsky R, Arensburg B, Kaffe I. Morphologic characteristics of bony edentulous jaws. J Prosthodont 2007;16:141 7.
- [11] Carruthers J, Carruthers A. Botulinum toxin in facial rejuvenation: An update. Dermatol Clin 2009; 27:417 25.
- [12] Cheek Plumper Denture for ‘Sunken Cheeks’ : a case report Jadhav Vivek1, Kale Sweta2, Kulkarni Manisha3 May - August 2014 | Volume 01 | Issue 02.